



A Prospective Comparison of Procedural Sedation and Ultrasound-guided Interscalene Nerve Block for Shoulder Reduction in the Emergency Department

Michael Blaivas, MD, Srikar Adhikari, MD, RDMS, and Lina Lander, ScD

Abstract

Objectives: Emergency physicians (EPs) are beginning to use ultrasound (US) guidance to perform regional nerve blocks. The primary objective of this study was to compare length of stay (LOS) in patients randomized to US-guided interscalene block or procedural sedation to facilitate reduction of shoulder dislocation in the emergency department (ED). The secondary objectives were to compare one-on-one health care provider time, pain experienced by the patient during reduction, and patient satisfaction between the two groups.

Methods: This was a prospective, randomized study of patients presenting to the ED with shoulder dislocation. The study was conducted at an academic Level I trauma center ED with an annual census of approximately 80,000. Patients were eligible for the study if they were at least 18 years of age and required reduction of a shoulder dislocation. A convenience sample of patients was randomized to either traditional procedural sedation or US-guided interscalene nerve block. Procedural sedation was performed with etomidate as the sole agent. Interscalene blocks were performed by hospital-credentialed EPs using sterile technique and a SonoSite MicroMaxx US machine with a high-frequency linear array transducer. Categorical variables were evaluated using Fisher's exact test, and continuous variables were analyzed using the Wilcoxon rank sum test.

Results: Forty-two patients were enrolled, with 21 patients randomized to each group. The groups were not significantly different with respect to sex or age. The mean (\pm SD) LOS in the ED was significantly higher in the procedural sedation group (177.3 ± 37.9 min) than in the US-guided interscalene block group (100.3 ± 28.2 minutes; $p < 0.0001$). The mean (\pm SD) one-on-one health care provider time was 47.1 (± 9.8) minutes for the sedation group and 5 (± 0.7) minutes for the US-guided interscalene block group ($p < 0.0001$). There was no statistically significant difference between the two groups in patient satisfaction or pain experienced during the procedure. There were no significant differences between groups with respect to complications such as hypoxia or hypotension ($p = 0.49$).

Conclusions: In this study, patients undergoing shoulder dislocation reduction using US-guided interscalene block spent less time in the ED and required less one-on-one health care provider time compared to those receiving procedural sedation. There was no difference in pain level or satisfaction when compared to procedural sedation patients.

ACADEMIC EMERGENCY MEDICINE 2011; 18:922-927 © 2011 by the Society for Academic Emergency Medicine

Emergency physicians (EPs) are frequently called on to treat patients who have suffered a shoulder dislocation. Shoulder dislocation is the most common dislocation encountered in the emergency

department (ED) population, occurring in 0.5% to 1.7% of individuals.^{1,2} Procedural sedation is routinely used in the ED to facilitate shoulder dislocation reduction. Reduction techniques that do not require any sedation

From the Department of Emergency Medicine, Northside Hospital-Forsyth (MB), Cumming, GA; the Department of Emergency Medicine, University of Arizona Health Sciences Center (SA), Tucson, AZ; and the Department of Epidemiology, University of Nebraska Medical Center (LL), Omaha, NE.

Received November 10, 2010; revision received February 7, 2011; accepted February 16, 2011.

The authors have no relevant financial information or potential conflicts of interest to disclose.

Supervising Editor: Thomas G. Costantino, MD.

Address for correspondence and reprints: Michael Blaivas, MD; e-mail: mike@blaivas.org.

have been described in the literature and are used sporadically by EPs. More often, some form of sedation is used for muscle relaxation.^{3,4} Currently propofol and etomidate are commonly used for procedural sedation, replacing the longer-acting agents such as morphine and midazolam.^{5,6}

While procedural sedation offers patient comfort and muscle relaxation to facilitate shoulder reduction, there are associated risks. These risks include hypotension, aspiration, and respiratory depression, among others.⁷ Such risks are minimized by standard protocols in many EDs that mandate cardiac, blood pressure, oxygen saturation, and end-tidal CO₂ monitoring.⁸ However, this requires one-on-one nursing care and may require use of certain “critical care” or higher-acuity rooms within an ED. Many EDs are not designed with full monitoring equipment and airway support capability in each room and thus patients may have to be moved.

Regional nerve anesthesia is frequently used as an adjunct to general anesthesia for shoulder surgery.^{9,10} Regional nerve blocks have traditionally been performed blindly and require specialized equipment such as nerve stimulators that are typically not found in the ED.¹¹ However, ultrasound (US) guidance is becoming an increasingly popular technique to facilitate regional nerve blocks in anesthesia practice.^{12,13} Recently, multiple reports have appeared describing the use of US-guided nerve blocks by EPs.^{14–16} This may hold significant advantages over procedural sedation in many ED settings. The primary objective of this study was to compare length of stay (LOS) in patients randomized to US-guided interscalene block or procedural sedation to facilitate reduction of shoulder dislocation in the ED. The secondary objectives were to compare one-on-one health care provider time, pain experienced by the patient during reduction, and patient satisfaction between the two groups.

METHODS

Study Design

This was a prospective, randomized study of patients presenting to the ED with shoulder dislocation. The study was approved by the institutional review board with written informed consent obtained from each patient.

Study Setting and Population

The study was conducted at an academic Level I trauma center ED with an annual census of approximately 80,000. The ED has an emergency medicine residency program and an active US education program. Patients were eligible for the study if they were 18 years of age or older and required reduction of a shoulder dislocation in the ED. We excluded patients if they had known allergy to local anesthetic agents, hemodynamic instability, or respiratory distress or were unable to give consent because of altered mental status. Patients were randomized to either traditional procedural sedation or US-guided interscalene nerve block groups. Randomization was performed using a random number generator. Patients were enrolled on a convenience basis based on researcher availability.

Study Protocol

Ultrasound-guided interscalene nerve blocks were performed by two EPs credentialed by the hospital to perform bedside US examinations following American College of Emergency Physicians US guidelines.¹⁷ These physicians received specialized training in US-guided regional anesthesia from a commercial US course. The education consisted of a 2-hour didactic course focusing on regional anesthesia applications, including the interscalene block, followed by hands-on training. All had at least 2 years of US experience in the ED before the study, and each had performed at least 10 interscalene blocks before the study.

Procedural sedation was performed using etomidate as the sole agent, by physicians with hospital credentialing for procedural sedation. All procedural sedation patients received sedation in critical care rooms in the ED. Hemodynamic monitoring included blood pressure, cardiac, and pulse oximetry monitoring. End-tidal CO₂ monitoring was not used in our facility at this time. Following hospital procedures, at least one physician and one nurse were required to be present with the patient during the procedural sedation. A nurse was also required to stay with the patient one on one during the recovery period. Recovery requires the patient being able to converse, drink fluids, and ambulate. One-on-one nursing time was recorded on a hospital procedural sedation form that tracked vital signs and recovery measures in a standard manner.

Interscalene blocks were performed using sterile technique and a SonoSite MicroMaxx (SonoSite, Inc., Bothell, WA) with a high-frequency (10–5 MHz) linear array transducer. Neurovascular checks were performed prior to attempting the block to confirm absence of neurologic deficits. A sterile cover was used over the transducer along with sterile US gel. The patient's ipsilateral neck was prepped with Betadine or chlorhexidine prior to the procedure. EPs acquired standard images of the brachial plexus in the interscalene position using a short-axis view of the nerves (Figure 1). Confirmation imaging was performed using anatomical landmarks and power Doppler to verify that targets were not vascular structures. Twenty-one-gauge 1.5-inch noncutting needles were used to deliver regional anesthetic to the brachial plexus (Figure 2). Twenty to 30 mL of anesthetic was injected, enough to envelope the nerve roots on US. The spread of local anesthetic was visualized in real time using US to monitor the hypoechoic signal dispersal around the nerve roots. Lidocaine with epinephrine was chosen over bupivacaine for its shorter duration of action. Block effectiveness was tested 15 minutes after completion of the US-guided nerve block and then in 10-minute intervals after. The physicians performed light touch and pin prick testing in a descending pattern from the shoulder into the arm. When skin anesthesia was present, complete anesthesia was tested with gentle shoulder palpation and then movement. After patients reported complete absence of pain, they were judged ready for the procedure. The physicians did not wait for complete distal anesthesia and paralysis, as in our experience this is not required for shoulder reduction.

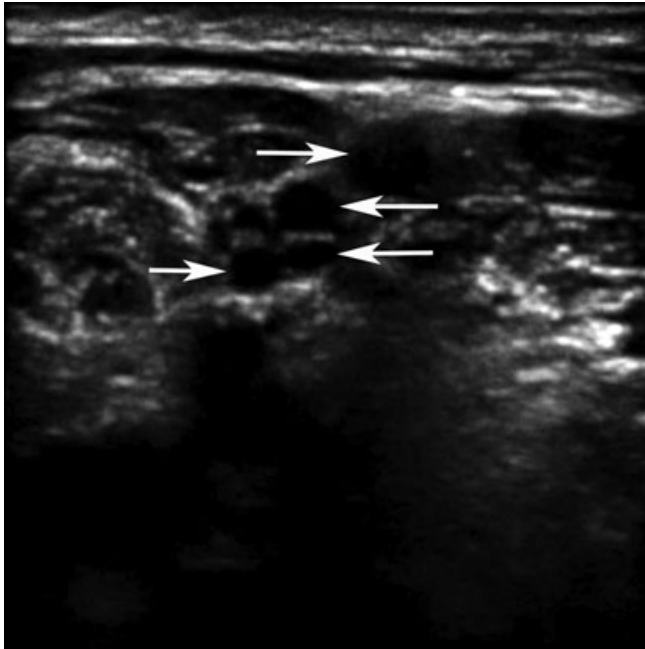


Figure 1. The interscalene location for the brachial plexus is shown on this US image. Arrows identify the heads of the plexus; in this case four separate nerves are seen. US = ultrasound.

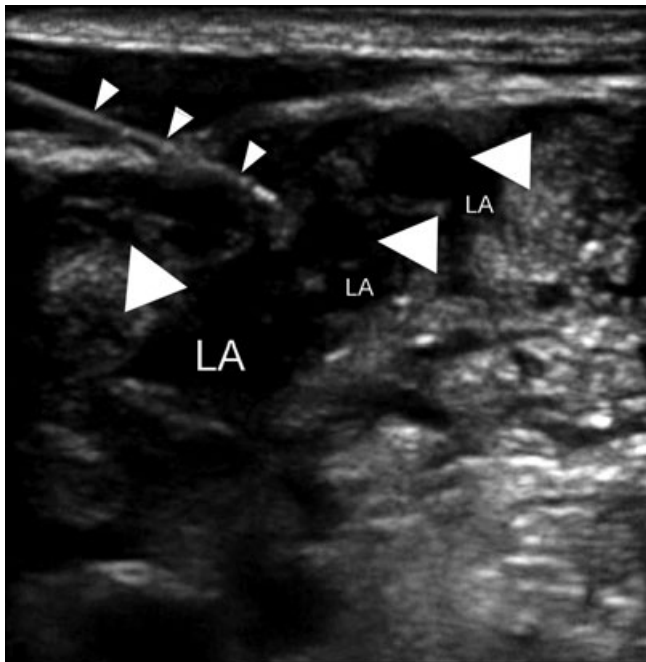


Figure 2. A needle (*small arrowheads*) is shown approaching the brachial plexus (*large arrowheads*) at the interscalene location. Local anesthetic agent (LA) has started to be injected and envelops some of the nerves.

Nursing help was not required while performing the block.

ED technicians assisted with shoulder reduction in both groups. The interscalene blocks or procedural sedation were performed by the same EP who

performed shoulder dislocation reduction. Patients randomized to US-guided interscalene nerve block group were monitored for complications such as hypotension, hypoxia, Horner's syndrome, hoarseness, and diaphragmatic symptoms during their ED stay by the treating EP. Patients randomized to the procedural sedation group were monitored for hypotension and hypoxia by the nurse involved in the patient care. Following the procedure, patients were asked to rate their associated pain using a visual analog scale (VAS; on a scale of 0 to 10, with 0 representing no pain and 10 representing the worst pain). In addition, patients were asked to rate their satisfaction with service provided regarding the orthopedic procedure prior to discharge on a standard 10-point VAS, with 1 representing "extremely dissatisfied" and 10 "extremely satisfied." The pain and satisfaction scores were obtained by researchers prior to patient discharge, when the patients were fully recovered. Data were collected using a standardized data extraction form that included information such as patient demographics, the need for additional analgesia, any adverse reactions, LOS in the ED, nursing time, and time taken to perform US-guided interscalene block.

Outcomes

Our primary outcome in this study was LOS in the ED. Secondary outcome variables included one-on-one health care provider time, pain experienced by the patient during reduction, and patient satisfaction. LOS was defined as the time between entry into a room in the ED to the time of discharge from ED. One-on-one health care provider time was defined as total time spent by either the nurse or EP monitoring the patient.

Data Analysis

Categorical variables were evaluated using Fisher's exact test, and continuous variables were analyzed using the Wilcoxon rank sum test. All analyses were performed in SAS Version 9.1 (SAS Institute Inc., Cary, NC). A p value of <0.05 was considered as statistically significant. Sample size was calculated based on prior studies comparing procedural sedation to alternate techniques. Approximately 20 patients in each group was determined to have 90% power at $\alpha = 0.05$ (two-tailed) to detect a 30-minute difference in LOS in the ED.

RESULTS

Forty-two patients were enrolled, with 21 patients randomized to the procedural sedation group and 21 to the US-guided interscalene block group. US-guided interscalene block was successfully performed in all patients randomized to that group. The reductions in the procedural sedation group were performed by nine different physicians and in the US-guided interscalene nerve block group by seven physicians. The success rate for reduction was 100% in both groups. The patient groups were not significantly different with respect to sex or age. There were six (29%) women in the procedural sedation group and five (24%) in the US-guided interscalene block group ($p = 0.99$). On average, patients in

Table 1
Comparison of Outcome Measures of Two Randomized Groups

	Procedural Sedation Group (n = 21)	US-guided Interscalene Block Group (n = 21)	p-value
LOS, mean (\pm SD)	177.3 (\pm 37.9)	100.3 (\pm 28.2)	<0.0001
Health care provider one-on-one time, mean (\pm SD)	47.1 (\pm 9.8)	5 (\pm 0.7)	<0.0001
Patient satisfaction, mean (\pm SD)	8.2 (\pm 1.3)	8.3 (\pm 1.1)	0.9275
Pain, median (range)	0 (0–4)	0 (0–3)	0.7990
O ₂ saturation < 95%, n (%)	2 (10)	0	0.4878
Hypotension, n (%)	2 (10)	0	0.4878

Time is reported in minutes.
LOS = length of stay; US = ultrasound.

the procedural sedation group were 35.9 (\pm 15.1) years old, and patients in the US-guided interscalene block group were 39 (\pm 19.7) years old ($p = 0.88$; Table 1). The mean (\pm SD) LOS in the ED was significantly higher in the procedural sedation group (177.3 \pm 37.9 minutes), compared to in the US-guided interscalene block group (100.3 \pm 28.2 minutes; $p < 0.0001$). The one-on-one health care provider time was 47.1 (\pm 9.8) minutes on average for the sedation group and 5 (\pm 0.7) minutes for the US-guided interscalene block group ($p < 0.0001$).

The patient satisfaction and pain scores were similar for patients in the two groups. Patient satisfaction ranged from 5 to 10 (median, 9) for the procedural sedation and 6 to 10 (median, 8) for the US-guided interscalene block group. The mean (\pm SD) patient satisfaction scores were 8.2 (\pm 1.3) for the sedation group and 8.3 (\pm 1.1) for the US-guided interscalene block group ($p = 0.93$). The self-reported pain scores ranged from 0 to 4 (median, 0) for the procedural sedation and 0 to 3 (median, 0) for the US-guided interscalene block group ($p = 0.80$).

There were no significant differences between groups with respect to complications such as hypoxia or hypotension ($p = 0.49$). No rescue interventions were required during procedural sedation. None of the subjects in the US-guided interscalene block required additional analgesia or sedation while performing shoulder reduction. Transient motor paralysis occurred in all patients who received US-guided interscalene block. The exact duration of the motor paralysis was not recorded. The patients were not followed up after discharge. However, no return ED visits were identified on chart review for persistent residual motor paralysis. None of the patients who received interscalene block developed complications such as Horner's syndrome, hoarseness, or symptoms related to diaphragmatic paralysis.

DISCUSSION

The requirements for documentation, monitoring, and nurse involvement for procedural sedation have grown significantly over the past two decades in response to increased calls for patient safety and medical treatment monitoring.¹⁸ Preprocedural fasting, continuous hemodynamic monitoring, and observation during postpro-

cedural recovery frequently result in prolonged ED stay.¹⁹ Concurrently, an increasing number of EDs around the country face overcrowding and increasing waiting room times, as well as prolonged ED LOS.^{20,21} Procedural sedation requires considerable documentation and close monitoring on the part of any nurse involved. Recent evidence suggests that increasing nursing staff workload contributes to increased LOS in the ED.^{22,23} With limited staffing in many busy EDs in the country, removal of one nurse from the number designated to an ED can significantly slow the overall flow. While patient safety cannot be overlooked, it might be helpful to explore safe alternatives such as regional anesthesia to decrease LOS in the ED. There may be additional advantages of regional nerve blockade over procedural sedation. Complications such as respiratory depression and aspiration can potentially be avoided with US-guided regional anesthesia.

Due to the lack of nerve stimulation equipment, most EPs historically have not performed regional nerve blocks such as interscalene, axillary, and femoral nerve blocks. With the development of US guidance for regional nerve anesthesia, EPs have been increasingly using US for this purpose.^{24–26} The effectiveness of regional nerve anesthesia under US guidance has been well described in the emergency medicine and anesthesia literature.^{27–31} The success rates for regional nerve blocks under US guidance have actually been shown to be higher compared to traditional approaches.^{32,33}

Prior studies using US-guided regional nerve anesthesia have suggested decreased LOS. Although limited by small numbers, Stone et al.³⁴ showed a marked decrease in LOS for US-guided nerve block patients. Our study also demonstrated decreased LOS in the US-guided interscalene block group. Additionally, there was a significant difference in one-on-one health care provider time between two groups. Our data analyses failed to find any significant difference in patient satisfaction, pain scores, or complication rates between the two groups. Our study results indicate the potential benefits of using US-guided regional anesthesia for shoulder dislocation in the ED.

Interscalene blocks have been well studied and frequently used in shoulder surgery. Hence, in our study we decided to use interscalene blocks instead of other techniques such as suprascapular block. While not

encountered in our study, the complications from interscalene block include hematoma, nerve penetration, and possible intravascular injection of anesthesia. These complications can be minimized with proper US guidance technique. However, one that is still periodically encountered is involvement of nearby nerves such as the recurrent laryngeal and phrenic nerves. Select patients who may be compromised by transient ipsilateral vocal cord or diaphragm paralysis may need to be counseled or even avoid the procedure altogether.

LIMITATIONS

Neither participants nor investigators were blinded to interventions. Since the investigators were not blinded to the interventions, it is possible that they assisted with certain components that would have decreased the LOS in the interscalene block group. The total ED LOS might have been influenced by other factors unrelated to the intervention, such as time to being seen by physician, time to obtain an x-ray, and time to finding a special room for procedural sedation.

Unfortunately we did not keep track of the reduction technique used, actual time of reduction, and exact time from the beginning of nerve block or procedural sedation until discharge. ED settings vary, and our setting may not be representative of other emergency medicine practice environments. Another limitation of the study is the convenience-sample design, which introduces a selection bias. Patients were enrolled in the study when credentialed EP sonologists were on duty. The information regarding the total number of ED patients with shoulder dislocation during the study period was not available to the study investigators. We did not compare interscalene block to other methods of analgesia such as intraarticular lidocaine. Since patients were not followed-up after the discharge, no information was available regarding long-term complications from the interscalene block. Our study physicians may have more scanning experience compared to an average EP sonologist, which may limit the generalizability of these results. Finally, the relatively small sample size limits the conclusions that can be reached from the study. A future prospective study with a large sample would allow broader generalizations.

CONCLUSIONS

In this study, patients undergoing shoulder dislocation reduction using ultrasound-guided interscalene block spent less time in the ED and required less one-on-one health care provider time compared to procedural sedation. There was no difference in pain level or satisfaction when compared to procedural sedation patients.

The authors thank Dr. Matt Lyon, Medical College of Georgia, for help in conducting this study.

References

1. Perron AD, Ingerski MS, Brady WJ, Erling BF, Ullman EA. Acute complications associated with

- shoulder dislocation at an academic emergency department. *J Emerg Med.* 2003; 24:141-5.
2. Milgrom C, Mann G, Finestone A. A prevalence study of recurrent shoulder dislocations in young adults. *J Shoulder Elbow Surg.* 1998; 7:621-4.
3. Orlinsky M, Shon S, Chiang C, Chan L, Carter P. Comparative study of intra-articular lidocaine and intravenous meperidine/diazepam for shoulder dislocations. *J Emerg Med.* 2002; 22:241-5.
4. Matthews DE, Roberts T. Intraarticular lidocaine versus intravenous analgesic for reduction of acute anterior shoulder dislocations. A prospective randomized study. *Am J Sports Med.* 1995; 23:54-8.
5. Burton JH, Bock AJ, Strout TD, Marcolini EG. Etomidate and midazolam for reduction of anterior shoulder dislocation: a randomized, controlled trial. *Ann Emerg Med.* 2002; 40:496-504.
6. Taylor D, O'Brien D, Ritchie P, Pasco J, Cameron P. Propofol versus midazolam/fentanyl for reduction of anterior shoulder dislocation. *Acad Emerg Med.* 2004; 12:13-9.
7. Roback MG, Wathen JE, Bajaj L, Bothner JP. Adverse events associated with procedural sedation and analgesia in a pediatric emergency department: a comparison of common parenteral drugs. *Acad Emerg Med.* 2005; 12:508-13.
8. Godwin SA, Caro DA, Wolf SJ, et al. American College of Emergency Physicians Clinical policy: procedural sedation and analgesia in the emergency department. *Ann Emerg Med.* 2005; 45:177-96.
9. Borgeat A, Ekatothramis G. Anaesthesia for shoulder surgery. *Best Pract Res Clin Anaesthesiol.* 2002; 16:211-25.
10. Singelyn FJ, Lhotel L, Fabre B. Pain relief after arthroscopic shoulder surgery: a comparison of intraarticular analgesia, suprascapular nerve block, and interscalene brachial plexus block. *Anesth Analg.* 2004; 99:589-92.
11. Urmey WF. Using the nerve stimulator for peripheral or plexus nerve blocks. *Minerva Anesthesiol.* 2006; 72:467-71.
12. Davis JJ, Swenson JD, Greis PE, Burks RT, Tashjian RZ. Interscalene block for postoperative analgesia using only ultrasound guidance: the outcome in 200 patients. *J Clin Anesth.* 2009; 21:272-7.
13. Liu SS, Zayas VM, Gordon MA, et al. A prospective, randomized, controlled trial comparing ultrasound versus nerve stimulator guidance for interscalene block for ambulatory shoulder surgery for postoperative neurological symptoms. *Anesth Analg.* 2009; 109:265-71.
14. Blaivas M, Lyon M. Ultrasound-guided interscalene block for shoulder dislocation reduction in the ED. *Am J Emerg Med.* 2006; 24:293-6.
15. Beaudoin FL, Nagdev A, Merchant RC, Becker BM. Ultrasound-guided femoral nerve blocks in elderly patients with hip fractures. *Am J Emerg Med.* 2010; 28:76-81.
16. Reid N, Stella J, Ryan M, Ragg M. Use of ultrasound to facilitate accurate femoral nerve block in the emergency department. *Emerg Med Australas.* 2009; 21:124-30.

17. American College of Emergency Physicians. Emergency ultrasound guidelines. *Ann Emerg Med.* 2009; 53:550–70.
18. Swoboda TK, Muniyak J. Use of a sedation-analgesia datasheet in closed shoulder reductions. *J Emerg Med.* 2005; 29:129–35.
19. Green SM, Krauss B. Pulmonary aspiration risk during emergency department procedural sedation—an examination of the role of fasting and sedation depth. *Acad Emerg Med.* 2002; 9:35–42.
20. Horwitz LI, Green J, Bradley EH. US emergency department performance on wait time and length of visit. *Ann Emerg Med.* 2010; 55:133–41.
21. Herring A, Wilper A, Himmelstein DU, et al. Increasing length of stay among adult visits to US emergency departments, 2001–2005. *Acad Emerg Med.* 2009; 16:609–16.
22. Robinson KS, Jagim MM, Ray CE. Nursing workforce issues and trends affecting emergency departments. *Nurs Manage.* 2005; 36:46–53.
23. Robinson K. Nursing's perfect storm—staff shortages and patient ratios. *J Emerg Nurs.* 2003; 29:199–200.
24. Liebmann O, Price D, Mills C, et al. Feasibility of forearm ultrasonography-guided nerve blocks of the radial, ulnar, and median nerves for hand procedures in the emergency department. *Ann Emerg Med.* 2006; 48:558–62.
25. Wathen JE, Gao D, Merritt G, Georgopoulos G, Battan FK. A randomized controlled trial comparing a fascia iliaca compartment nerve block to a traditional systemic analgesic for femur fractures in a pediatric emergency department. *Ann Emerg Med.* 2007; 50:162–71.
26. Herring A, Price DD, Nagdev A, Simon B. Superior cluneal nerve block for treatment of buttock abscesses in the emergency department. *J Emerg Med.* 2010; 39:83–5.
27. Christiansen TG, Nielsen R. Reduction of shoulder dislocations under interscalene brachial blockade. *Arch Orthop Trauma Surg.* 1988; 107:176–7.
28. Stone MB, Price DD, Wang R. Ultrasound-guided supraclavicular block for the treatment of upper extremity fractures, dislocations, and abscesses in the ED. *Am J Emerg Med.* 2007; 25:472–5.
29. Chan VW. Applying ultrasound imaging to interscalene brachial plexus block. *Reg Anesth Pain Med.* 2003; 28:340–3.
30. Chan VW, Perlas A, Rawson R, Odukoya O. Ultrasound-guided supraclavicular brachial plexus block. *Anesth Analg.* 2003; 97:1514–7.
31. De Andres J, Sala-Blanch X. Ultrasound in the practice of brachial plexus anesthesia. *Reg Anesth Pain Med.* 2002; 27:77–89.
32. Williams SR, Chouinard P, Arcand G, et al. Ultrasound guidance speeds execution and improves the quality of supraclavicular block. *Anesth Analg.* 2003; 97:1518–23.
33. Kapral S, Greher M, Huber G, et al. Ultrasonographic guidance improves the success rate of interscalene brachial plexus blockade. *Reg Anesth Pain Med.* 2008; 33:253–8.
34. Stone MB, Wang R, Price DD. Ultrasound-guided supraclavicular brachial plexus nerve block vs procedural sedation for the treatment of upper extremity emergencies. *Am J Emerg Med.* 2008; 26:706–10.

Academic Emergency Medicine on the Wiley Online Library Platform

Make sure you keep checking the journal's home page on the recently implemented platform, Wiley Online Library (WOL) - [http://onlinelibrary.wiley.com/journal/10.1111/\(ISSN\)1553-2712](http://onlinelibrary.wiley.com/journal/10.1111/(ISSN)1553-2712).

Many new features appear in the form of “modules” and will be updated on a regular basis. The new platform is more robust and easier to navigate, with enhanced online functionality.

Visit often and stay tuned for updates!